



Pyogenic Vertebral Osteomyelitis: Clinical Features, Diagnosis, and Treatment

Ji-Woong Kwon¹,
Seung-Jae Hyun²,
Sang-Hyun Han²,
Ki-Jeong Kim²,
Tae-Ahn Jahng²

¹Neuro-Oncology Clinic, National Cancer Center, Goyang,

²Department of Neurosurgery, Spine Center, Seoul National University Bundang Hospital, Seoul National University College of Medicine, Seongnam, Korea

Corresponding Author:

Seung-Jae Hyun

Department of Neurosurgery, Spine Center, Seoul National University Bundang Hospital, Seoul National University College of Medicine, 82 Gumi-ro 173beon-gil, Bundang-gu, Seongnam 13620, Korea

Tel: +82-31-787-7164

Fax: +82-31-787-4059

E-mail: hyunsj@snu.ac.kr

Received: April 3, 2017

Revised: April 7, 2017

Accepted: June 20, 2017

Copyright © 2017 by The Korean Spinal Neurosurgery Society

This is an open access article distributed under the terms of the Creative Commons Attribution Non-Commercial License (<http://creativecommons.org/licenses/by-nc/4.0/>) which permits unrestricted non-commercial use, distribution, and reproduction in any medium, provided the original work is properly cited.

Pyogenic vertebral osteomyelitis (PVO) may result in neurological deficits and sequelae, so early diagnosis and appropriate treatment are critical. Many previous studies on PVO exist, but our paper has aimed to comprehensively summarize the clinical aspects of PVO. Through review of the vast literature on the clinical research of PVO an overview of the clinical characteristics, diagnostic methods, treatment and prognosis is provided.

Key Words: Pyogenic vertebral osteomyelitis, Causative organism, Diagnosis, Antibiotic treatment, Prognosis

INTRODUCTION

Vertebral osteomyelitis (OM) is an uncommon infectious condition of the spine and various terms such as spondylodiscitis, septic discitis, and spinal OM have been used⁹⁸. The incidence has been rising recently assumed to be due to aging society, increase in the number of immune compromised subjects^{1,41,63}. The incidence has been reported to be 2.2 to 5.8 per 100,000 and highest in men aged 70-79 years^{33,41}, and the overall incidence increases with aging. In the population older than 20 years, the male predominance in incidence increases until the age of 80 years³³. Despite the great number of literature on the topic, there is still controversy regarding various aspects of diagnosis and treatment. Through this paper, the clinical features, methods of diagnosis, and steps of treatment will be reviewed based on up to date literatures. Especially, the review focused on pyogenic vertebral osteomyelitis (PVO) with the exception of spinal tuberculosis.

CLINICAL PRESENTATION

The most common symptom of PVO is axial back pain or neck pain. More than 80% of the patients present with rather severe pain not controlled by analgesics^{2,31,36}. The onset of the pain is usually insidious and duration may be as long as several months. Epidural abscess should be considered in patients with severe, sharp, or lancinating type of back pain^{20,85,98}. Local tenderness or spasm of the paraspinal muscles may be evident in physical examina-

tion^{13,63}. Neurological deficits including motor weakness and sensory loss are not as common, ranging from 10% to 50%^{12,26,36,42,53,57}. Fever may be present but is not a necessary condition. Various reports have shown 35% to 60% of the patients have fever on presentation^{69,79}.

The fact that there may be a site of primary infection in PVO patients should be considered. Symptoms from the primary source may precede the typical back pain of vertebral myelitis itself. In approximately half of the patients, the primary infection site may be identified: skin, respiratory, oral, urinary tract, gastrointestinal tract, vascular access site, endocarditis or arthritis⁶⁹. Endocarditis was found in as many as 1/3 of the PVO patients⁷⁸. Several study reported about 19% to 47% of patients had undergone spinal surgery before PVO diagnosis^{16,62,96}.

Many of the patients with PVO have underlying diseases such as diabetes mellitus, coronary artery diseases, immune-suppressed condition, and cancer^{62,69,96}.

Differential diagnosis for back patients include degenerative spinal diseases, vertebral fractures or disc herniation, inflammatory spinal diseases, and metastatic tumor from systemic tumors^{13,98}. In cases of back pain with fever, viral syndromes, pyelonephritis, and pancreatitis should also be considered⁹⁸.

Because the symptoms and signs of PVO are usually nonspecific, and not infrequently fever is not seen, the correct diagnosis may not be made until almost 1 year since the onset of symptoms^{5,12,66,70}. It is crucial that clinicians should always consider PVO as one of the disease entities of differential diagnosis.

LABORATORY FINDINGS

Leukocytosis or high proportion (>80%) of neutrophils is not sensitive for diagnosis of OM^{36,38}. Nevertheless those laboratory results may be helpful as part of the routine work up for infection or fever, as well as markers to evaluate the treatment response². In contrast, increase in erythrocyte sedimentation rate (ESR) and C-reactive protein (CRP) were noted to be very helpful, with sensitivity of 98% and 100%, respectively^{38,43}.

Although ESR is not specific for infection, it rises in inflammatory condition, therefore may suggest the possibility of infection and may show the treatment response of the patient⁹. CRP has more specificity on infection than ESR because it rises within 6 hours of a bacterial infection⁹. It also normalizes more quickly than ESR after adequate treatment on the infection. These parameters are commonly increased after surgical procedures without any complications due to normal inflammatory reactions. However in these cases, ESR peaks at approximately 5 days after the operation and normalizes within 3 weeks, and CRP reaches maximal value at 2–3 days postoperatively and returns to normal limits during 6–14 postoperative days^{42,86}. Therefore, Elevation of ESR and CRP is not pathognomonic feature of infection but those are useful as screening tests and also as monitoring parameters for treatment response.

RADIOLOGIC FINDINGS

Plain radiography is useful as the initial evaluation tool to screen a wide range of possible diseases because it is easily accessed, but is not sensitive for OM⁹⁸. Blurring of end-plate and decrease in disc space may be detected in the early phase but because many patients have underlying degenerative changes in the spine, it is not easy to suspect OM based on these findings⁹.

Magnetic resonance imaging (MRI) should be considered as the initial tool in patients with neurological deficits to rule out epidural abscess or herniation of the intervertebral disc⁹⁸. MRI is the gold standard to diagnosis spinal infection with sensitivity,

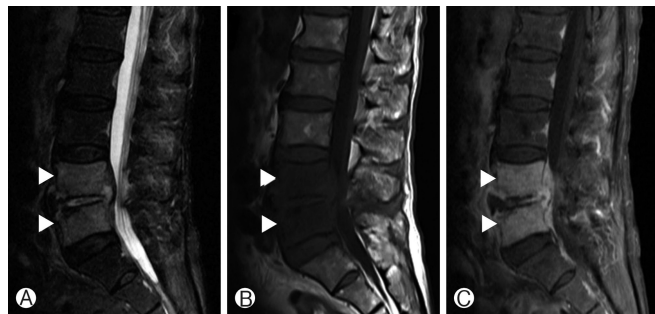


Fig. 1. Magnetic resonance imaging of lumbar pyogenic vertebral osteomyelitis case. T2-weighted 1 sagittal image (A), T1-weighted 1 (T1W1) sagittal image (B), and T1WI sagittal image (C) with enhancement. Arrowheads indicate signal change of adjacent vertebrae.

specificity, and accuracy of over 90%². Destruction of endplate and marrow edema of the vertebral body results in decreased signal intensity (SI) of vertebral body, disc, and endplate on T1-weighted image (T1WI)^{22,26,91}, increased SI of vertebral body and disc on T2-weighted image (T2WI), and contrast enhancement^{55,72}. Typical cases show involvement the disc and 2 adjacent vertebral bodies (Fig. 1). In postoperative patients, the above-mentioned features should be interpreted with care because slight signal changes may be seen in the remaining discs in cases of noncomplicated discectomy, making the differentiation of early discitis and normal postoperative change difficult. When the adjacent vertebral body shows low SI on T1WI along with contrast enhancement, infection may be more likely⁹. The MRI findings of a spinal tumor may be similar to PVO but may be differentiated by the fact that disc space is usually spared⁹. The MRI can be also helpful in distinguishing between PVO and tuberculous spondylitis. The findings on MRI are more frequently observed in PVO cases, which are less severe bony destruction, disc involvement, ill-defined postcontrast paraspinal abnormal signal margin, disc abscess with peridiscal rim enhancement and homogeneous enhancement of the vertebral body⁸. On the contrary, more severe bone destruction with relative disc preservation, focal heterogeneous contrast enhancement of the vertebral body, well-defined abnormal SI in paraspinal areas, and vertebral intraosseous abscess with rim enhancement are distinctive MRI findings of tuberculous spondylitis⁸.

Although MRI is more sensitive than computed tomography (CT) especially for early diagnosis of OM, CT scan may be utilized for those patients in whom MRI is contraindicated or percutaneous biopsy is needed⁹⁸. Also, CT may be helpful in deciding the extent of debridement of infected, necrotic tissues, because MRI may overestimate the extent of disease involvement⁹.

Three-phase technetium-99m bone scan show positive results, a few days after the symptom onset with high sensitivity of 90% but the specificity is rather low, 78%⁸². The scan may show increased activity for osteoporotic fractures, tumor and even after the spondylitis is cured with normalization of the laboratory findings⁹. Ga-67 scintigraphy with single-photon-emission CT seems to show similar accuracy with MRI, but is less sensitive for detecting epidural abscess⁶⁴. Indium 111-labeled leukocyte scintigraphy and antigranulocyte scintigraphy are very sensitive for detecting PVO but have very low specificities (<20%)^{2,72}. Not many studies on 18F-fluorodeoxyglucose positron emission tomography are available, but very high sensitivity (100%) and specificity (100%) for diagnosing disc space infection have been reported, and may be utilized to differentiate OM and degenerative changes⁸⁸. It may be an especially better choice in patients with metallic implants⁹⁸.

CAUSATIVE ORGANISMS

Most of PVO is caused by a single organism. However, polymicrobial infection is found in less than 10% of the patients^{69,87} usually with underlying decubitus ulcer, chronic debility and im-

immune compromise^{12,42}.

Staphylococcus aureus was the most common causative bacteria according to numerous reports^{14,20,30,93}. Among the *S. aureus*, the prevalence of methicillin-resistant *Staphylococcus aureus* (MRSA) seems to be increasing recently compared to previous data, up to 40%–57.1%^{6,61,67,73}. Male sex, multiple comorbidities and previous non-spine surgery were significant risk factors for PVO due to MRSA as compared to methicillin-sensitive *Staphylococcus aureus* (MSSA)³⁷. Gram-negative rod was identified in 7%–33% of the patients, enterobacteriaceae being the most common species^{6,19,34,57}. Gram-negative rod may be the causative organism more frequently in patients with genitourinary tract, gastrointestinal tract infection, old-age, compromised immune status, and diabetes¹³.

Coagulase-negative staphylococci are also found in 5%–16% of PVO, and staphylococcus epidermidis is most common. Frequently it is associated with postoperative infection or intracardiac device-related sepsis²⁰, and is more likely to be found in patients with symptoms presenting more than 1 month after the operation³². Streptococci and enterococci may also be identified in 5%–20% of PVO cases^{34,57} and is frequently related with dental port of entry or endocarditis, whereas staphylococci are less commonly found in PVO patients with endocarditis¹³. The less virulent *Staphylococcus epidermidis* and viridans streptococci may cause indolent infections³¹. Although anaerobe is responsible for only 3% of PVO, it is more common in diabetes patients².

IDENTIFICATION OF CAUSATIVE ORGANISMS

Identification of the causative organism is imperative because appropriate choice of the antimicrobial agent is crucial for treatment. Blood culture should be performed initially for all patients regardless of the presence of fever. Blood cultures are reported to have diagnostic value in 30%–78% of PVO cases⁶⁹ meaning further invasive procedures may not be necessary in those patients with positive blood culture results. Other body fluids such as urine and sputum as well as swabs from any portals of entry should be evaluated and cultured to find the primary focus of the infection¹³. When causative organism is not identified with blood culture or other samples in patients who are suspected with PVO on radiological evaluation, biopsy to directly obtain the infected tissue is necessary. Percutaneous biopsy using CT or fluoroscope guidance can be performed, or biopsy with direct inspection of the involved tissue using endoscope or open surgery may be done. If polymicrobial OM is suspected, biopsy is mandatory regardless of the results of blood culture^{74,98}. In patients with paravertebral, epidural, or psoas abscess, drainage of the abscess may be done instead of disc or bone biopsy to identify the organism⁹⁸.

Biopsy specimens are known to have higher overall diagnostic yield (47%–100%), regardless of the method of biopsy⁶⁹. Culture for aerobic, anaerobic bacteria, and fungi must be done for biopsy samples⁹⁸. Evaluation for mycobacteria or brucella

species should be done in patients living in endemic areas or those with subacute presentations^{12,77}.

False negative blood culture or biopsy results are frequently found in patients who were treated with empirical antibiotics before microbiological diagnosis. Second biopsy should be performed when the initial culture results are negative^{23,27}. With the exception of the acutely ill patients with definite symptoms or signs of sepsis or abscess, antimicrobial treatment should not be initiated until the causative organism is identified⁹⁸. It is recommended that even those patients who were treated with antibiotics before identification of causative organism, if the patient is stable, biopsy should be postponed for at least 48 hours from the last injection or intake of antibiotic⁹⁸. Some studies have shown that an even longer antibiotic-free period of 1–2 weeks will increase the yield rate of the biopsy, but it is not recommended in OM patients because of acutely-ill, critical condition of acute OM patients⁹⁸. If the results of closed technique biopsy are repeatedly negative in patients in whom OM is highly likely, open biopsy should be considered^{31,98}. Open biopsy showed positive culture results in over 75% of cases^{2,39,53,67,86}. In a few prospective studies, the proportion of spine infections with negative culture results was reported to be 21%–34%^{14,66,87}.

However, various reports have shown that the treatment duration, mortality, and recurrence rate do not seem to differ between the patients with identification of the causative organism and those without^{46,63,89,96}. Similarly, the data from the authors' institute also show that the yield of a second biopsy in patients with negative results from a first fluoroscopy-guided biopsy was only 7.6% (2 out of 26 patients)⁴⁵. Although the importance of identification of the causative organism should not be underestimated, the above results show that the patient's risk and economic burden of repetitive biopsy should be considered with caution. Histopathological examination may also provide useful information. The presence of white blood cells in the infected tissue may differentiate between infection and contamination, and granuloma may suggest atypical causes such as brucellosis or tuberculosis⁹⁸.

Molecular diagnostics are not routinely utilized for OM. However, broad-range polymerase chain reaction (PCR) analysis of organisms may be used when available, if blood and biopsy culture results are negative²¹. PCR analysis may find microorganisms not detectable by classic culture methods^{21,54,92}. A recent study reported that 16S rDNA PCR assay may be more sensitive than routine culture in etiological diagnosis OM¹¹.

ANTIMICROBIAL TREATMENT

There are yet no randomized control trials regarding antibiotic treatment of PVO. The choice of antibiotics for PVO treatment should target the identified causative organism when possible, and factors such as bone and disc penetration capability, potential side effects, and administration feasibility should be considered¹³. For gram-positive bacteria, intravenous therapy is still the standard therapy. If causative organism is not identified,

broad spectrum antibiotics with antistaphylococcal coverage, as well as coverage for clinically suspected organism is recommended^{28,86}. The outcome of early switch to oral antibiotics is controversial but oral bactericidal agents with high bioavailability and bone penetration such as clindamycin and fluoroquinolones may enable early administration of oral agents^{3,76,83}. Beta-lactam antibiotics on the other hand, should not be used as an oral antibiotic for OM because of its low bioavailability.

No controlled trial data is available on the optimal treatment duration, but usually 4–6 weeks^{81,98}, up to 3 months^{61,77} are recommended. In the presence of undrained abscess or spinal prosthesis, longer duration of antibiotic treatment is desired^{49,99,100}. One study suggested the disappearance of inflammatory patterns and spinal pain, along with normalization of the body temperature, CRP and/or ESR, and improvement in plain radiography as indicators for termination of antibiotic administration⁵⁷.

IMMOBILIZATION

Bed rest during the initial 2–4 weeks followed by ambulation with appropriate brace or corset is recommended in patients with severe, acute pain^{32,53}. External immobilization helps stabilization of the spine, reduction of pain and prevents deformity⁹. The appropriate duration of bracing may vary from 3–6 weeks, up to 3 months, and should be decided according to individual patient's degree of bone destruction and deformity^{9,13}.

SURGERY

Mostly, the goal of surgery for OM is diagnosis (biopsy)⁶⁹ but may itself have therapeutic roles in cases with compression of the cord or cauda equina showing progressive neurologic deficits. Urgent surgical decompression should be considered because preoperative neurologic status is the important predictor of the final neurologic outcome in spinal epidural abscess patients^{15,65}. Surgery should also be considered in cases where diagnosis is not confirmed, poor response to appropriate treatment is seen, or progressive deformity of the spine causing instability is noted.

Surgical debridement is almost always required in infections associated with spinal prosthesis⁴⁹. Removal of the prosthesis is further recommended for the late onset infection patients whose symptoms presented more than 30 days after the instrumentation surgery, because presence of prosthesis decreases the treatment success rate⁴⁹.

Spinal infection may result in severe bone destruction and deformity, in which internal fixation of structural stabilization may be necessary. However, surgeons may be reluctant to instrumentation of an infected spine because prosthesis may hinder the antimicrobial treatment. Recent studies focusing on this issue have reported the usefulness and stability of internal fixation in active PVO^{52,56,60,80}.

Autograft, allograft, titanium mesh cage may be used as materials for anterior column support and bony fusion, allograft

and titanium mesh cages have not been popular due to the abovementioned reasons. Several studies have proved favorable outcomes in infection control as well as spinal stability of PVO patients who had allograft or titanium mesh cage implanted^{35,48,58,84}. It should be emphasized that in such patients thorough, aggressive removal of the infected tissue combined with appropriate antibiotic treatment is mandatory to obtain good outcome.

The surgical approach for operation in PVO is worth considering. In many studies, the anterior and posterior approach (combined approach) was performed and proved to be safe and efficient^{24,48,52,58,75}. One study had shown the combined approach had advantages in terms of hospitalization period and loss of correction compared to anterior or posterior only approach⁷¹. However another study proved superiority of ventral stabilization via single anterior approach versus ventro-dorsal fusion in long term outcome⁶⁰. In addition there are several studies that good clinical outcome was achieved via single approach^{25,29,47,59,95}. Thus the type of surgical approach needs to be tailored according to patient general medical condition, degree of bony destruction and location of compressive lesions.

The utilization of intrawound vancomycin powder during spinal surgery has become popular to prevent surgical site infection (SSI)¹⁸. Several meta-analyses had suggested that intrawound vancomycin powder could be effective to reduce SSI after spinal operation^{4,10,40,44}. However those meta-analyses were limited in that they included studies with low level of evidence (grade III or IV) and had heterogeneity in the clinical settings, such as definition of SSI, method of vancomycin powder application, type of surgery, perioperative antibiotics regimen, etc. One prospective randomized controlled study proved intrawound usage of vancomycin powder did not significantly reduce the incidence of SSI in spinal surgery⁹⁰. A recent study aimed at 9,823 patients revealed about 50% reduction of SSI in intrawound antibiotics using group on unadjusted analysis, but this difference was not statistically significant after adjustment¹⁷. So far, the evidence on the benefit of intrawound vancomycin in spinal surgery is uncertain. It will be interesting to see the results of ongoing prospective clinical trials related to application of intrawound vancomycin in spinal surgery (<http://ClinicalTrials.gov>; NCT01566422; NCT01977989)^{10,40}.

FOLLOW-UP AND OUTCOMES

Response to treatment can be evaluated with improvement of clinical symptoms such as pain and fever or laboratory study, and radiologic imaging. When definite improvement in the clinical symptom and laboratory parameters is observed in response to treatment, follow-up evaluation with MRI or CT is usually not necessary. The correlation between improvement of MRI findings and clinical recovery is not strong^{7,97}. In one study, there were 85% of the patients whose MRI taken 4–8 weeks after the initiation of treatment showed no change or improvement had improved clinically⁵⁰, and no single MR finding was

associated with the patients' clinical status⁵¹). Therefore follow-up MRI should be selectively performed for those patients who do not show clinical improvement despite adequate treatment or when epidural abscess is suspected⁸⁵). The disappearance of contrast enhancement and recovery of normal SI are reliable MRI features of complete healing. It should be kept in mind that even after complete resolution of the clinical infection, uptake of contrast on the MRI may reside for several months^{2,94}). MRI should be repeated before terminating antibiotic treatment in case of a nonsurgically treated abscess⁹⁸).

Various studies report successful treatment rate of 50%–91% with antibiotics for PVO^{42,53,81,94}). Good prognosis is expected for those patients who show decrease in ESR and weekly decrement of CRP by 50% during the first month of treatment^{26,32}). In contrast, no relief of symptoms or consistent CRP value of above 30mg/L may indicate treatment failure^{43,50}).

PVO related mortality is reported to be 2%–11%^{12,39,53,68}). The severity of comorbidity, age over 60 years, high CRP value at admission (≥ 100 mg/L) are known related factors to higher mortality^{62,68}). Another series reported that delay in diagnosis of more than 2 months, neurological deficit such as paralysis or paresis, and nosocomial infection were related to death or permanent deficits⁶⁸). Some reports The PVO caused by MRSA showed more persistent bacteremia, relapse, increased hospital stay compared to those caused by MSSA⁷³).

In one study of 253 patients, the relapse rate was approximately 14% and related factors were recurrent bacteremia, chronic draining sinuses, paravertebral abscesses⁶⁸). In another study, the mortality between PVO patients with or without endocarditis was not different but the relapse rate was significantly higher for those with endocarditis (8% vs. 1.9%)⁷⁸). Relapse of PVO may occur as late as 1 year after the completion of treatment^{13,39}), therefore follow-up for sufficient period after treatment is mandatory.

CONCLUSION

The incidence of PVO has been increasing lately so although a rare condition, clinicians should consider it in patients with unremitting back pain and increase in inflammatory marker. When PVO is suspected, MRI should be performed promptly and culture study to identify the causative organism is crucial. Treatment should be specified according to culture results, so if the patient's condition is tolerable, antimicrobial agents should not be administered before identification of the organism. Although data from randomized control trials regarding antibiotics regimen and administration period are lacking, 6-week period of treatment is routinely recommended and longer periods for patients with complicated infection or spinal implants.

CONFLICT OF INTEREST

No potential conflict of interest relevant to this article was reported.

REFERENCES

- Acosta FL Jr, Chin CT, Quinones-Hinojosa A, Ames CP, Weinstein PR, Chou D: Diagnosis and management of adult pyogenic osteomyelitis of the cervical spine. **Neurosurg Focus** 17:E2, 2004
- An HS, Seldomridge JA: Spinal infections: diagnostic tests and imaging studies. **Clin Orthop Relat Res** 444:27-33, 2006
- Babouee Flury B, Elzi L, Kolbe M, Frei R, Weisser M, Scharen S, et al: Is switching to an oral antibiotic regimen safe after 2 weeks of intravenous treatment for primary bacterial vertebral osteomyelitis? **BMC Infect Dis** 14:226, 2014
- Bakhsheshian J, Dahdaleh NS, Lam SK, Savage JW, Smith ZA: The use of vancomycin powder in modern spine surgery: systematic review and meta-analysis of the clinical evidence. **World Neurosurg** 83:816-823, 2015
- Bateman JL, Pevzner MM: Spinal osteomyelitis: a review of 10 years' experience. **Orthopedics** 18:561-565, 1995
- Bhavan KP, Marschall J, Olsen MA, Fraser VJ, Wright NM, Warren DK: The epidemiology of hematogenous vertebral osteomyelitis: a cohort study in a tertiary care hospital. **BMC Infect Dis** 10:158, 2010
- Carragee EJ: The clinical use of magnetic resonance imaging in pyogenic vertebral osteomyelitis. **Spine (Phila Pa 1976)** 22:780-785, 1997
- Chang MC, Wu HT, Lee CH, Liu CL, Chen TH: Tuberculous spondylitis and pyogenic spondylitis: comparative magnetic resonance imaging features. **Spine (Phila Pa 1976)** 31:782-788, 2006
- Cheung WY, Luk KD: Pyogenic spondylitis. **Int Orthop** 36:397-404, 2012
- Chiang HY, Herwaldt LA, Blevins AE, Cho E, Schweizer ML: Effectiveness of local vancomycin powder to decrease surgical site infections: a meta-analysis. **Spine J** 14:397-407, 2014
- Choi SH, Sung H, Kim SH, Lee SO, Lee SH, Kim YS, et al: Usefulness of a direct 16S rRNA gene PCR assay of percutaneous biopsies or aspirates for etiological diagnosis of vertebral osteomyelitis. **Diagn Microbiol Infect Dis** 78:75-78, 2014
- Colmenero JD, Jimenez-Mejias ME, Sanchez-Lora FJ, Reguera JM, Palomino-Nicas J, Martos F, et al: Pyogenic, tuberculous, and brucellar vertebral osteomyelitis: a descriptive and comparative study of 219 cases. **Ann Rheum Dis** 56:709-715, 1997
- Cottle L, Riordan T: Infectious spondylodiscitis. **J Infect** 56:401-412, 2008
- D'Agostino C, Scorzolini L, Massetti AP, Carnevalini M, d'Ettore G, Venditti M, et al: A seven-year prospective study on spondylodiscitis: epidemiological and microbiological features. **Infection** 38:102-107, 2010
- Darouiche RO: Spinal epidural abscess. **N Engl J Med** 355:2012-2020, 2006
- Dufour V, Feydy A, Rillardon L, Redondo A, Le Page L, Bert F, et al: Comparative study of postoperative and spontaneous pyogenic spondylodiscitis. **Semin Arthritis Rheum** 34:766-771, 2005
- Ehlers AP, Khor S, Shonnard N, Oskouian RJ Jr, Sethi RK, Cizik AM, et al: Intra-wound antibiotics and infection in spine fusion surgery: a report from Washington State's SCOAP-CERTAIN Collaborative. **Surg Infect (Larchmt)** 17:179-186, 2016
- Emohare O, Ledonio CG, Hill BW, Davis RA, Polly DW Jr, Kang MM: Cost savings analysis of intrawound vancomycin powder in

- posterior spinal surgery. *Spine J* 14:2710-2715, 2014
19. Euba G, Narvaez JA, Nolla JM, Murillo O, Narvaez J, Gomez-Vaquero C, et al: Long-term clinical and radiological magnetic resonance imaging outcome of abscess-associated spontaneous pyogenic vertebral osteomyelitis under conservative management. *Semin Arthritis Rheum* 38:28-40, 2008
 20. Fantoni M, Trecarichi EM, Rossi B, Mazzotta V, Di Giacomo G, Nasto LA, et al: Epidemiological and clinical features of pyogenic spondylodiscitis. *Eur Rev Med Pharmacol Sci* 16 Suppl 2:2-7, 2012
 21. Fenollar F, Levy PY, Raoult D: Usefulness of broad-range PCR for the diagnosis of osteoarticular infections. *Curr Opin Rheumatol* 20:463-470, 2008
 22. Forrester DM: Infectious spondylitis. *Semin Ultrasound CT MR* 25:461-473, 2004
 23. Friedman JA, Maher CO, Quast LM, McClelland RL, Ebersold MJ: Spontaneous disc space infections in adults. *Surg Neurol* 57: 81-86, 2002
 24. Fukuta S, Miyamoto K, Masuda T, Hosoe H, Kodama H, Nishimoto H, et al: Two-stage (posterior and anterior) surgical treatment using posterior spinal instrumentation for pyogenic and tuberculous spondylitis. *Spine (Phila Pa 1976)* 28:E302-308, 2003
 25. Fushimi K, Miyamoto K, Fukuta S, Hosoe H, Masuda T, Shimizu K: The surgical treatment of pyogenic spondylitis using posterior instrumentation without anterior debridement. *J Bone Joint Surg Br* 94:821-824, 2012
 26. Gasbarrini AL, Bertoldi E, Mazzetti M, Fini L, Terzi S, Gonella F, et al: Clinical features, diagnostic and therapeutic approaches to haematogenous vertebral osteomyelitis. *Eur Rev Med Pharmacol Sci* 9:53-66, 2005
 27. Gaudias J: Considerations on antimicrobial therapy for pyogenic discitis. *Joint Bone Spine* 68:463-465, 2001
 28. Gillard J, Boutoille D, Varin S, Asseray N, Berthelot JM, Maugars Y: Suspected disk space infection with negative microbiological tests-report of eight cases and comparison with documented pyogenic discitis. *Joint Bone Spine* 72:156-162, 2005
 29. Gorensek M, Kosak R, Travnik L, Vengust R: Posterior instrumentation, anterior column reconstruction with single posterior approach for treatment of pyogenic osteomyelitis of thoracic and lumbar spine. *Eur Spine J* 22:633-641, 2013
 30. Gouliouris T, Aliyu SH, Brown NM: Spondylodiscitis: update on diagnosis and management. *J Antimicrob Chemother* 65 Suppl 3: iii11-24, 2010
 31. Govender S: Spinal infections. *J Bone Joint Surg Br* 87:1454-1458, 2005
 32. Grados F, Lescure FX, Senneville E, Flipo RM, Schmit JL, Fardellone P: Suggestions for managing pyogenic (non-tuberculous) discitis in adults. *Joint Bone Spine* 74:133-139, 2007
 33. Grammatico L, Baron S, Rusch E, Lepage B, Surer N, Desenclos JC, et al: Epidemiology of vertebral osteomyelitis (VO) in France: analysis of hospital-discharge data 2002-2003. *Epidemiol Infect* 136:653-660, 2008
 34. Hadjipavlou AG, Mader JT, Necessary JT, Muffoletto AJ: Hematogenous spinal infections and their surgical management. *Spine (Phila Pa 1976)* 25:1668-1679, 2000
 35. Hee HT, Majd ME, Holt RT, Pienkowski D: Better treatment of vertebral osteomyelitis using posterior stabilization and titanium mesh cages. *J Spinal Disord Tech* 15:149-156; discussion 156, 2002
 36. Hopkinson N, Stevenson J, Benjamin S: A case ascertainment study of septic discitis: clinical, microbiological and radiological features. *QJM* 94:465-470, 2001
 37. Inoue S, Moriyama T, Horinouchi Y, Tachibana T, Okada F, Maruo K, et al: Comparison of clinical features and outcomes of staphylococcus aureus vertebral osteomyelitis caused by methicillin-resistant and methicillin-sensitive strains. *Springerplus* 2:283, 2013
 38. Jensen AG, Espersen F, Skinhoj P, Fridmodt-Moller N: Bacteremic Staphylococcus aureus spondylitis. *Arch Intern Med* 158:509-517, 1998
 39. Jimenez-Mejias ME, de Dios Colmenero J, Sanchez-Lora FJ, Palomino-Nicas J, Reguera JM, Garcia de la Heras J, et al: Postoperative spondylodiscitis: etiology, clinical findings, prognosis, and comparison with nonoperative pyogenic spondylodiscitis. *Clin Infect Dis* 29:339-345, 1999
 40. Kang DG, Holekamp TF, Wagner SC, Lehman RA Jr: Intraspinal vancomycin powder for the prevention of surgical site infection in spine surgery: a systematic literature review. *Spine J* 15:762-770, 2015
 41. Kehler M, Pedersen C, Jensen TG, Lassen AT: Increasing incidence of pyogenic spondylodiscitis: a 14-year population-based study. *J Infect* 68:313-320, 2014
 42. Khan IA, Vaccaro AR, Zlotolow DA: Management of vertebral diskitis and osteomyelitis. *Orthopedics* 22:758-765, 1999
 43. Khan MH, Smith PN, Rao N, Donaldson WF: Serum C-reactive protein levels correlate with clinical response in patients treated with antibiotics for wound infections after spinal surgery. *Spine J* 6:311-315, 2006
 44. Khan NR, Thompson CJ, DeCuyper M, Angotti JM, Kalobwe E, Muhlbauer MS, et al: A meta-analysis of spinal surgical site infection and vancomycin powder. *J Neurosurg Spine* 21:974-983, 2014
 45. Kim BJ, Lee JW, Kim SJ, Lee GY, Kang HS: Diagnostic yield of fluoroscopy-guided biopsy for infectious spondylitis. *AJNR Am J Neuroradiol* 34:233-238, 2013
 46. Kim J, Kim YS, Peck KR, Kim ES, Cho SY, Ha YE, et al: Outcome of culture-negative pyogenic vertebral osteomyelitis: Comparison with microbiologically confirmed pyogenic vertebral osteomyelitis. *Semin Arthritis Rheum* 44:246-252, 2014
 47. Kim YM, Choi SM: Posterior only approach for lumbar pyogenic spondylitis with short instrumentation and prolonged suction drainage. *Spine (Phila Pa 1976)* 41:E1022-1029, 2016
 48. Korovessis P, Repantis T, Iliopoulos P, Hadjipavlou A: Beneficial influence of titanium mesh cage on infection healing and spinal reconstruction in hematogenous septic spondylitis: a retrospective analysis of surgical outcome of twenty-five consecutive cases and review of literature. *Spine (Phila Pa 1976)* 33:E759-767, 2008
 49. Kowalski TJ, Berbari EF, Huddleston PM, Steckelberg JM, Mandrekar JN, Osmon DR: The management and outcome of spinal implant infections: contemporary retrospective cohort study. *Clin Infect Dis* 44:913-920, 2007
 50. Kowalski TJ, Berbari EF, Huddleston PM, Steckelberg JM, Osmon DR: Do follow-up imaging examinations provide useful prognostic information in patients with spine infection? *Clin Infect Dis* 43: 172-179, 2006
 51. Kowalski TJ, Layton KF, Berbari EF, Steckelberg JM, Huddleston PM, Wald JT, et al: Follow-up MR imaging in patients with pyogenic spine infections: lack of correlation with clinical features. *AJNR Am J Neuroradiol* 28:693-699, 2007

52. Kuklo TR, Potter BK, Bell RS, Moquin RR, Rosner MK: Single-stage treatment of pyogenic spinal infection with titanium mesh cages. *J Spinal Disord Tech* **19**:376-382, 2006
53. Lam KS, Webb JK: Discitis. *Hosp Med* **65**:280-286, 2004
54. Lecouvet F, Irengé L, Vandercam B, Nzeusseu A, Hamels S, Gala JL: The etiologic diagnosis of infectious discitis is improved by amplification-based DNA analysis. *Arthritis Rheum* **50**:2985-2994, 2004
55. Ledermann HP, Schweitzer ME, Morrison WB, Carrino JA: MR imaging findings in spinal infections: rules or myths? *Radiology* **228**:506-514, 2003
56. Lee MC, Wang MY, Fessler RG, Liauw J, Kim DH: Instrumentation in patients with spinal infection. *Neurosurg Focus* **17**:E7, 2004
57. Legrand E, Flipo RM, Guggenbuhl P, Masson C, Mailliefert JF, Soubrier M, et al: Management of nontuberculous infectious discitis. treatments used in 110 patients admitted to 12 teaching hospitals in France. *Joint Bone Spine* **68**:504-509, 2001
58. Liljenqvist U, Lerner T, Bullmann V, Hackenberg L, Halm H, Winkelmann W: Titanium cages in the surgical treatment of severe vertebral osteomyelitis. *Eur Spine J* **12**:606-612, 2003
59. Lin CP, Ma HL, Wang ST, Liu CL, Yu WK, Chang MC: Surgical results of long posterior fixation with short fusion in the treatment of pyogenic spondylodiscitis of the thoracic and lumbar spine: a retrospective study. *Spine (Phila Pa 1976)* **37**:E1572-1579, 2012
60. Linhardt O, Matussek J, Refior HJ, Krodel A: Long-term results of ventro-dorsal versus ventral instrumentation fusion in the treatment of spondylitis. *Int Orthop* **31**:113-119, 2007
61. Livorsi DJ, Daver NG, Atmar RL, Shelburne SA, White AC Jr, Musher DM: Outcomes of treatment for hematogenous Staphylococcus aureus vertebral osteomyelitis in the MRSA ERA. *J Infect* **57**:128-131, 2008
62. Loibl M, Stoyanov L, Doenitz C, Brawanski A, Wiggermann P, Krusch W, et al: Outcome-related co-factors in 105 cases of vertebral osteomyelitis in a tertiary care hospital. *Infection* **42**:503-510, 2014
63. Lora-Tamayo J, Euba G, Narvaez JA, Murillo O, Verdaguer R, Sobrino B, et al: Changing trends in the epidemiology of pyogenic vertebral osteomyelitis: the impact of cases with no microbiologic diagnosis. *Semin Arthritis Rheum* **41**:247-255, 2011
64. Love C, Patel M, Lonner BS, Tomas MB, Palestro CJ: Diagnosing spinal osteomyelitis: a comparison of bone and Ga-67 scintigraphy and magnetic resonance imaging. *Clin Nucl Med* **25**:963-977, 2000
65. Lu CH, Chang WN, Lui CC, Lee PY, Chang HW: Adult spinal epidural abscess: clinical features and prognostic factors. *Clin Neurol Neurosurg* **104**:306-310, 2002
66. Luzzati R, Giacomazzi D, Danzi MC, Tacconi L, Concia E, Vento S: Diagnosis, management and outcome of clinically-suspected spinal infection. *J Infect* **58**:259-265, 2009
67. Marschall J, Bhavan KP, Olsen MA, Fraser VJ, Wright NM, Warren DK: The impact of prebiopsy antibiotics on pathogen recovery in hematogenous vertebral osteomyelitis. *Clin Infect Dis* **52**:867-872, 2011
68. McHenry MC, Easley KA, Locker GA: Vertebral osteomyelitis: long-term outcome for 253 patients from 7 Cleveland-area hospitals. *Clin Infect Dis* **34**:1342-1350, 2002
69. Mylona E, Samarkos M, Kakalou E, Fanourgiakis P, Skoutelis A: Pyogenic vertebral osteomyelitis: a systematic review of clinical characteristics. *Semin Arthritis Rheum* **39**:10-17, 2009
70. Nolla JM, Ariza J, Gomez-Vaquero C, Fiter J, Bermejo J, Valverde J, et al: Spontaneous pyogenic vertebral osteomyelitis in nondrug users. *Semin Arthritis Rheum* **31**:271-278, 2002
71. Okada Y, Miyamoto H, Uno K, Sumi M: Clinical and radiological outcome of surgery for pyogenic and tuberculous spondylitis: comparisons of surgical techniques and disease types. *J Neurosurg Spine* **11**:620-627, 2009
72. Palestro CJ, Love C, Miller TT: Infection and musculoskeletal conditions: Imaging of musculoskeletal infections. *Best Pract Res Clin Rheumatol* **20**:1197-1218, 2006
73. Park KH, Chong YP, Kim SH, Lee SO, Choi SH, Lee MS, et al: Clinical characteristics and therapeutic outcomes of hematogenous vertebral osteomyelitis caused by methicillin-resistant Staphylococcus aureus. *J Infect* **67**:556-564, 2013
74. Patzakis MJ, Rao S, Wilkins J, Moore TM, Harvey PJ: Analysis of 61 cases of vertebral osteomyelitis. *Clin Orthop Relat Res (264)*: 178-183, 1991
75. Pee YH, Park JD, Choi YG, Lee SH: Anterior debridement and fusion followed by posterior pedicle screw fixation in pyogenic spondylodiscitis: autologous iliac bone strut versus cage. *J Neurosurg Spine* **8**:405-412, 2008
76. Perlroth J, Kuo M, Tan J, Bayer AS, Miller LG: Adjunctive use of rifampin for the treatment of Staphylococcus aureus infections: a systematic review of the literature. *Arch Intern Med* **168**:805-819, 2008
77. Perronne C, Saba J, Behloul Z, Salmon-Ceron D, Lepout C, Vilde JL, et al: Pyogenic and tuberculous spondylodiscitis (vertebral osteomyelitis) in 80 adult patients. *Clin Infect Dis* **19**:746-750, 1994
78. Pigrau C, Almirante B, Flores X, Falco V, Rodriguez D, Gasser I, et al: Spontaneous pyogenic vertebral osteomyelitis and endocarditis: incidence, risk factors, and outcome. *Am J Med* **118**:1287, 2005
79. Priest DH, Peacock JE Jr: Hematogenous vertebral osteomyelitis due to Staphylococcus aureus in the adult: clinical features and therapeutic outcomes. *South Med J* **98**:854-862, 2005
80. Rayes M, Colen CB, Bahgat DA, Higashida T, Guthikonda M, Rengachary S, et al: Safety of instrumentation in patients with spinal infection. *J Neurosurg Spine* **12**:647-659, 2010
81. Roblot F, Besnier JM, Juhel L, Vidal C, Ragot S, Bastides F, et al: Optimal duration of antibiotic therapy in vertebral osteomyelitis. *Semin Arthritis Rheum* **36**:269-277, 2007
82. Rodiek SO: Diagnostic methods in spinal infections. *Radiologe* **41**:976-986, 2001
83. Schrenzel J, Harbarth S, Schockmel G, Genne D, Bregenzer T, Flueckiger U, et al: A randomized clinical trial to compare fleroxacin-rifampicin with flucloxacillin or vancomycin for the treatment of staphylococcal infection. *Clin Infect Dis* **39**:1285-1292, 2004
84. Schuster JM, Avellino AM, Mann FA, Girouard AA, Grady MS, Newell DW, et al: Use of structural allografts in spinal osteomyelitis: a review of 47 cases. *J Neurosurg* **93(1 Suppl)**:8-14, 2000
85. Sendi P, Bregenzer T, Zimmerli W: Spinal epidural abscess in clinical practice. *QJM* **101**:1-12, 2008
86. Silber JS, Anderson DG, Vaccaro AR, Anderson PA, McCormick P; NASS: Management of postprocedural discitis. *Spine J* **2**:279-287, 2002
87. Skaf GS, Domloj NT, Fehlings MG, Bouclaous CH, Sabbagh AS, Kanafani ZA, et al: Pyogenic spondylodiscitis: an overview. *J Infect*

- Public Health** 3:5-16, 2010
88. Stumpe KD, Zanetti M, Weishaupt D, Hodler J, Boos N, Von Schulthess GK: FDG positron emission tomography for differentiation of degenerative and infectious endplate abnormalities in the lumbar spine detected on MR imaging. **AJR Am J Roentgenol** 179:1151-1157, 2002
 89. Tachibana T, Moriyama T, Maruo K, Inoue S, Yoshiya S: Therapeutic impact of organism isolation in management of patients with pyogenic vertebral osteomyelitis. **Springerplus** 3:62, 2014
 90. Tubaki VR, Rajasekaran S, Shetty AP: Effects of using intravenous antibiotic only versus local intrawound vancomycin antibiotic powder application in addition to intravenous antibiotics on post-operative infection in spine surgery in 907 patients. **Spine (Phila Pa 1976)** 38:2149-2155, 2013
 91. Varma R, Lander P, Assaf A: Imaging of pyogenic infectious spondylodiskitis. **Radiol Clin North Am** 39:203-213, 2001
 92. Weber U, Morf MH, Gubler JG, Altwegg M, Maibach RC: Spondylodiscitis as the first manifestation of Whipple's disease -a removal worker with chronic low back pain. **Clin Rheumatol** 22:443-446, 2003
 93. Weissman S, Parker RD, Siddiqui W, Dykema S, Horvath J: Vertebral osteomyelitis: retrospective review of 11 years of experience. **Scand J Infect Dis** 46:193-199, 2014
 94. Wirtz DC, Genius I, Wildberger JE, Adam G, Zilkens KW, Nie-thard FU: Diagnostic and therapeutic management of lumbar and thoracic spondylodiscitis--an evaluation of 59 cases. **Arch Orthop Trauma Surg** 120:245-251, 2000
 95. Yaldz C, Ozdemir N, Yaman O, Feran HG, Tansug T, Minoglu M: A retrospective study of 39 patients treated with anterior approach of thoracic and lumbar spondylodiscitis: clinical manifestations, anterior surgical treatment, and outcome. **Medicine (Baltimore)** 94:e2110, 2015
 96. Yoon SH, Chung SK, Kim KJ, Kim HJ, Jin YJ, Kim HB: Pyogenic vertebral osteomyelitis: identification of microorganism and laboratory markers used to predict clinical outcome. **Eur Spine J** 19:575-582, 2010
 97. Zarrouk V, Feydy A, Salles F, Dufour V, Guigui P, Redondo A, et al: Imaging does not predict the clinical outcome of bacterial vertebral osteomyelitis. **Rheumatology (Oxford)** 46:292-295, 2007
 98. Zimmerli W: Clinical practice. Vertebral osteomyelitis. **N Engl J Med** 362:1022-1029, 2010
 99. Zimmerli W, Trampuz A, Ochsner PE: Prosthetic-joint infections. **N Engl J Med** 351:1645-1654, 2004
 100. Zimmerli W, Widmer AF, Blatter M, Frei R, Ochsner PE: Role of rifampin for treatment of orthopedic implant-related staphylococcal infections: a randomized controlled trial. Foreign-Body Infection (FBI) Study Group. **JAMA** 279:1537-1541, 1998