



## Original Article

### Corresponding Author

Sang-Min Lee

<https://orcid.org/0000-0002-2021-9128>

Department of Neurosurgery, Armed  
Forced Busan Hospital, 186 Seseil-ro,  
Haeundae-gu, Busan 48066, Korea  
Tel: +82-51-977-5777  
Fax: +82-51-977-5777  
E-mail: hole84@naver.com

Received: December 29, 2017

Revised: March 19, 2018

Accepted: April 17, 2018



This is an Open Access article distributed under the terms of the Creative Commons Attribution Non-Commercial License (<http://creativecommons.org/licenses/by-nc/4.0/>) which permits unrestricted non-commercial use, distribution, and reproduction in any medium, provided the original work is properly cited.

Copyright © 2018 by the Korean Spinal  
Neurosurgery Society

# The Characteristics and Incidence of Posterior Apophyseal Ring Fracture in Patients in Their Early Twenties With Herniated Lumbar Disc

Yoon Nae Seo<sup>1</sup>, Young Jin Heo<sup>2</sup>, Sang-Min Lee<sup>3</sup>

<sup>1</sup>Department of Radiology, Hanyang University Hanmaeum Changwon Hospital, Changwon, Korea

<sup>2</sup>Department of Radiology, Inje University Busan Paik Hospital, Busan, Korea

<sup>3</sup>Department of Neurosurgery, Armed Force Busan Hospital, Busan, Korea

**Objective:** Posterior apophyseal ring fracture (PARF) is a common disorder that may be accompanied by herniated lumbar disc (HLD) in patients in their early twenties. However, there are very few reports on PARF in this clinical context. The objective of this study was to identify the incidence and characteristics of PARF with HLD in this age group.

**Methods:** We surveyed patients who visited Armed Forces Busan Hospital between May 2017 and October 2017 and included those aged between 19 and 25 years who had HLD accompanied by PARF. We retrospectively collected their demographic characteristics, clinical manifestations, and radiological findings on computed tomography (CT) scans. We categorized the PARF lesions according to Takata's classification.

**Results:** Of 140 HLD patients, 43 (30.7%) had PARF lesions with HLD. We found that the presence of a PARF lesion was significantly related to a severe pain score on the visual analogue scale for lower back pain and/or lower leg radiating pain ( $p=0.001$ ). The most common level and location of PARF were L5/S1 ( $n=25$ , 56.8%) and the superior endplate of the S1 vertebra, respectively. Type 1, according to Takata's classification, was the most common type of PARF in the patients ( $n=34$ , 77.2%).

**Conclusion:** We recommend that spinal surgeons perform CT scans to check for PARF lesions in all young patients in their 20s who present with severe radiating and lower back pain.

**Keywords:** Epiphyseal plate, Growth plate, Intervertebral disk displacement, Low back pain

## INTRODUCTION

Lumbar posterior apophyseal ring fracture (PARF) is generally an uncommon disorder reported in adolescents and young adults having low back pain and neural symptoms. This disease was specifically diagnosed in young athletes and confirmed by separation of bony particle at the posterior edge of the cephalad or caudal vertebral endplate where apophyseal ring and adjoining vertebral body had been completely fused. This fusion becomes complete between the ages of 18 and 25 years.<sup>1-3</sup> Many neurosurgeons have not been familiar with this disease and not

everything about this disorder has been proved clearly. Therefore, there are only few articles about the incidence of this disorder some of which reported the incidence in all patients having herniation of the lumbar disc<sup>4-6</sup> while others appeared frequently in children and adolescents.<sup>7,8</sup> There are, however, no reports on its incidence in the age group of 18 to 25 years, when apophyseal rings and the adjoining vertebral bodies are not completely fused. Therefore, we studied the clinical and radiological features of PARF with herniated lumbar disc (HLD) in this age group.

## MATERIALS AND METHODS

We examined the patients who visited Armed Forces Busan Hospital between May 2017 and October 2017 and shortlisted those aged between 19 and 25 years having HLD accompanied with PARE. All patients were soldiers, and they had similar level of physical labor intensity. We excluded the patients with other spinal diseases, such as spondylolysis, spondylolisthesis, idiopathic adolescent scoliosis, and spinal stenosis. The Institutional Review Board of Armed forces medical research institutes approved this retrospective study protocol (AFMC-17105-IRB-098).

### 1. Demographic Characteristics and Histories

We retrospectively surveyed the patients for age, history of trauma, and any athletic activities in the past.

### 2. Clinical Manifestations at Admission

At admission, we assessed the severity of subjective discomforts about lower back pain or radiating pain using the visual analysis scale (VAS) and checked those having weakness of lower extremity, hypoesthesia, and increased deep tendon reflexes. We performed straight leg raise (SLR) test on all patients with lower back pain or radiating pain.

### 3. Radiological Analysis

We reviewed the computed tomography (CT) scans (with continuous slices, no gap and 5-mm slice thickness) of all HLD patients. We classified the degree and location of HLD according to lumbar disc nomenclature: version 2.0 of North American Spinal Society and used Takata et al.<sup>3</sup> classification to subdivide findings in patients with PARE. In this classification, there are three types in computed tomographic morphology.

The type 1 is simple separation of posterior vertebral endplate not containing the vertebral body, type 2 corresponds to an avulsion fracture of the posterior rim of vertebral body including the cartilage endplate of annulus fibrosus, and type 3 defined a small posterior vertebral body fracture larger than vertebral rim. One neurosurgeon and one radiologist crosschecked these findings, which were included in this article (Fig. 1).

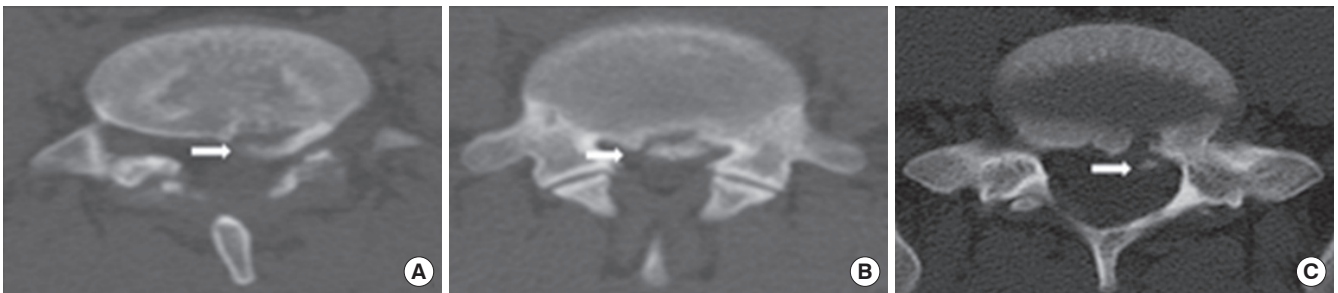### 4. Statistical Analyses

To ascertain factors associated with PARE, we used the chi-square test in all patients with HLD. The independent samples t-test and Mann-Whitney U-test were used to compare the average values amongst the patients with and without PARE. All statistical analyses were performed using SPSS ver. 12.0 (SPSS Inc., Chicago, IL, USA). All p-values < 0.05 were considered statistically significant.

## RESULTS

Of the patients visiting Armed Forces Busan Hospital, 140 were diagnosed with HLD, of which 43 patients had the associated PARE lesion (30.7%). Moreover, 176 HLD lesions were included in our study, of these, 44 lesions were accompanied PARE. Only male patients were included in our study, and the median age of each group showed similar results (with PARE: median age, 21 years; interquartile range [IQR], 20–22 years vs. without PARE: median age, 21 years; IQR, 20–21 years).

The characteristics of patients with PARE versus those without PARE are presented in Table 1. Amongst the clinical manifestations in each group, there was only one significant result in the severity of whole discomforts using VAS: median VAS 6 (4–7) in patients having PARE versus median VAS 4 (3–5) in patients without PARE. However, we did not find any significant



**Fig. 1.** Classification of posterior apophyseal ring fracture.<sup>22</sup> (A) Type 1, an arcuate simple avulsion of the posterior cortex of the endplate without osseous defect. (B) Type 2, an avulsion fracture of the central cortical and cancellous rim of posterior vertebra. (C) Type 3, a more lateral localized fracture involving a larger amount of the vertebral body, resulting that osseous defect anterior to the fragment is larger than the fragment. Arrow indicates the lesions of posterior apophyseal fracture.

**Table 1.** Demographic characteristics of the patents

Characteristic	With PARF (n = 43)	Without PARF (n = 97)	p-value
Age (yr)	21 (20–22)	21 (20–21)	0.932
Symptom			
LBP	41 (95.3)	95 (97.9)	0.586
Radiating pain	31 (72.1)	66 (68.0)	0.695
VAS	6 (4–7)	4 (3–5)	0.001
Past history			
Trauma	9 (20.9)	15 (15.5)	0.470
Young athlete	3 (7.0)	9 (9.3)	0.755
Neurologic exam			
Hypesthesia	2 (4.7)	3 (3.1)	0.643
Leg weakness	0 (0)	2 (2.1)	>0.999
Cauda equina syndrome	0 (0)	0 (0)	>0.999
SLR test	35 (81.4)	69 (71.1)	0.217
Multilevel	15 (34.9)	17 (17.5)	0.030
2 Level	15 (34.9)	16 (16.5)	0.026
3 Level	0 (0)	1 (1.0)	>0.999

Values are presented as median (interquartile range) or number (%). PARF, posterior apophyseal ring fracture; LBP, lower back pain; VAS, visual analogue scale; SD, syndrome; SLR, straight leg raised test.

statistical differences in other clinical symptoms. There were also no statistically meaningful results in neurological examination such as hypoesthesia, motor weakness of lower extremities, SLR test, and cauda equina syndrome. There were also no differences in past history of receiving trauma that patients have remembered such as fall down, traffic accidents, and blunt injury (20.9% vs. 15.5%,  $p=0.470$ ) and the experience of athletes in young ages (7.0% vs. 9.3%,  $p=0.755$ ).

Table 2 shows differences in the radiological findings between each group. The ratio of protrusion to extrusion remained the same in each group. The locations and directions of ruptured particle in the spinal canal did not reveal significant differences in each group. In the group having HLD without PARF, the most common level was L4/L5 (78 patients, 59.1%) followed by L5/S1 (52 patients, 39.2%). In the patients with PARF, the lesion was accompanied with HLD at the same spinal level. The most common level with PARF was L5/S1 ( $n=25$ , 56.8%) followed by L4/L5 ( $n=19$ , 43.2%). The incidence of PARF in multilevel discs in each group did not show a meaningful result.

Table 3 exhibits the detail about superior or inferior endplate of each vertebra where PARF occurred and the result that the morphologies of PARF were divided by Takada's classification. The locations of PARF were L4 inferior endplate in 4 patients, L5 superior endplate in 13, L5 inferior endplate in 6, and S1 superior endplate in 21. There was no patient who had multiple PARF lesion. According to Takada's criteria, type 1 was the most

**Table 2.** Radiologic findings of the patients

Variable	PARF (n = 44)	No PARF (n = 132)	p-value
Protrusion	43 (97.7)	129 (97.7)	>0.999
Extrusion	1 (2.3)	3 (2.3)	>0.999
Location			
Central	30 (68.2)	96 (72.7)	0.563
Subarticular	13 (29.5)	29 (22.0)	0.307
Foraminal	1 (2.3)	4 (3.0)	0.573
Direction			
Central	30 (68.2)	96 (72.7)	0.563
Right	7 (15.9)	15 (11.4)	0.430
Left	7 (15.9)	18 (13.6)	0.803
Level			
L3/L4	0 (0)	3 (2.3)	0.574
L4/L5	19 (43.2)	78 (59.1)	0.066
L5/S1	25 (56.8)	52 (39.2)	0.044
Multilevels	15 (34.1)	61 (46.2)	0.218
L3/L4	0 (0)	1 (0.8)	>0.999
L4/L5	7 (15.9)	32 (24.2)	0.299
L5/S1	8 (18.2)	28 (21.2)	0.826

Values are presented as number (%). PARF, posterior apophyseal ring fracture.

**Table 3.** The location and Takada's type of posterior apophyseal ring fractures

Location	Type 1	Type 2	Type 3	Type 4	Total
L4 inferior	2 (4.5)	0 (0)	2 (4.5)	0 (0)	4 (9.0)
L5 superior	10 (22.7)	3 (6.8)	0 (0)	0 (0)	13 (29.5)
L5 inferior	5 (11.4)	1 (2.3)	0 (0)	0 (0)	6 (13.6)
S1 superior	17 (38.6)	2 (4.5)	2 (4.5)	0 (0)	21 (47.7)
Total	34 (77.2)	6 (13.6)	4 (0.9)	0 (0)	44 (100)

Values are presented as number (%).

L4 inferior, 4th lumbar inferior endplate; L5 superior, 5th lumbar superior endplate; L5 inferior, 5th lumbar inferior endplate; S1 superior, 1st Sacral superior endplate.

common condition in PARF ( $n=34$ , 77.2%). In this type, the superior endplate of S1 was the most common site of occurrences ( $n=17$ , 50%). The second common type was type 2 ( $n=6$ , 13.6%), which mostly occurred at the superior endplate of L5 vertebra.

## DISCUSSION

The epiphyseal ring ossifies between the age of 4 to 6 years and fuses completely before the age of 18 to 25 years<sup>9</sup> approximately. It is strongly attached to the annulus fibrosus by Sharp-

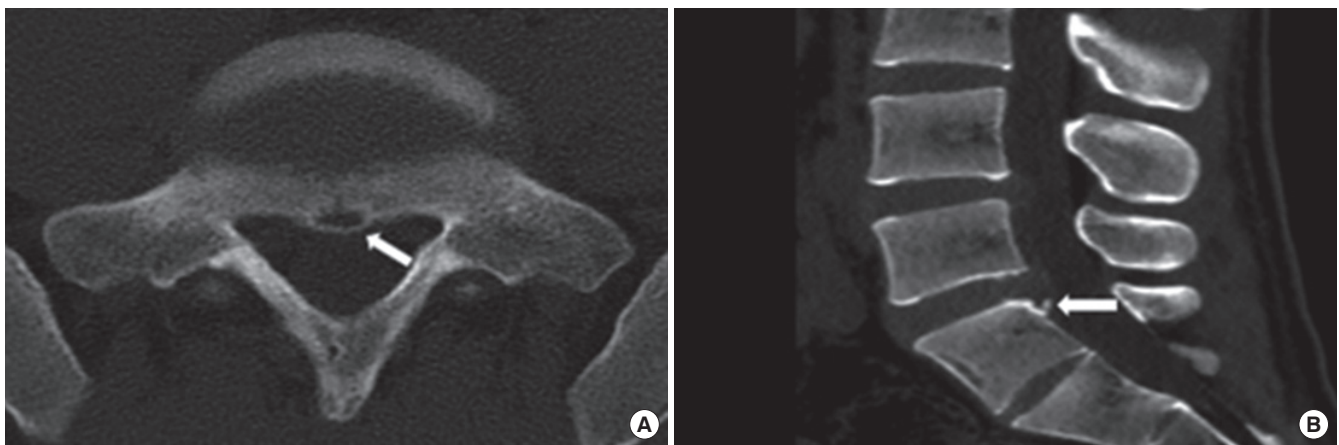
ey's fibers. The posterior longitudinal ligament wrapping the posterior part of vertebral body firmly holds onto annulus fibrosus. Consequently, the apophyseal ring is weakly joined to vertebral body; hence, PARF occurs. There are several hypotheses about the occurrence of PARF. Some authors have reported that sports trauma and injury such as weight lifting and falling caused the separation of apophyseal ring as they have frequently noted this condition in young athletes and patients with history of physical trauma.<sup>2,8,10-12</sup> Others revealed that repetitive extension is the mechanism of PARF. The large stress under this situation may damage and weaken the apophyseal ring in young ages and finally cause PARF, when it goes over the point that apophyseal ring physiologically endured.<sup>13,14</sup> The others reported that the pathogenesis of this disease is the degeneration of the intervertebral disc and cartilage.<sup>15,16</sup> We suggest the pathogenesis of this disease to be microtrauma and degeneration. In our reports, most patients with PARF had not been athletes and recalled the episode of recent trauma. Moreover, we did not find the radiological lesion associated with trauma. We noticed that all patients with PARF had HLD at the same level of vertebra.

Some authors have reported the incidence of PARF, but the results of these reports varied according to the patients' age. In all ages, the incidence of PARF accompanied with HLD was 5.35%–8.2%.<sup>4-6</sup> Some revealed that the prevalence of PARF in children and adolescents was 5.8%–28%.<sup>7,8</sup> Scarfo et al.<sup>16</sup> reported that 11% of patients with HLD were diagnosed with PARF. In our reports, PARF lesion was diagnosed in 43 patients with HLD, who were in their young twenties (30.7%). The difference in incidence was caused by the fact that PARF cannot be easily detected on plain radiograph and magnetic resonance

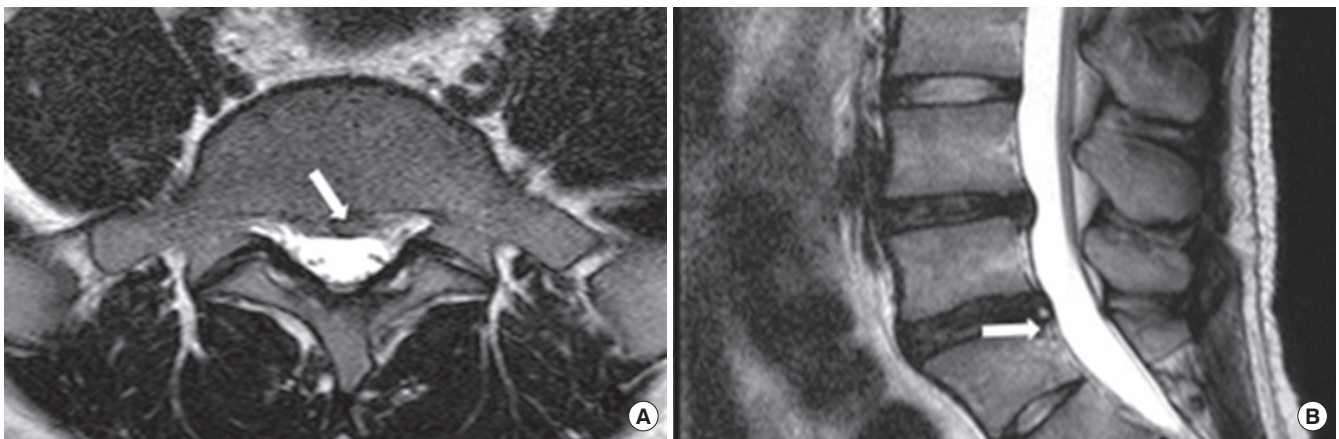
imaging (MRI).<sup>17,18</sup> Moreover, the other reason of this difference was that many spine surgeons were unfamiliar with this lesion and confused it with ossification of posterior longitudinal ligament, calcified intervertebral disc, and degenerative osteophytes. The report of Martínez-Lage et al.<sup>8</sup> and our reports noticed that the incidence in patients with unfused apophyseal ring was higher than that in adults. Our reports showed the highest incidence of PARF in these articles about the incidence of PARF; so, the incidence of this disease is expected to increase until 25 years old when apophyseal ring is completely fused.

The most common symptoms of PARF are lower back pain with or without radiating pain due to nerve root irritation.<sup>5,7,15,17,19</sup> Other symptoms are paravertebral muscle spasm and tenderness, the decreased motor power in lower extremity or/and sensory defect, and loss of deep tendon reflexes according to the affected nerve. However, cauda equina syndrome is a rare symptom in the patients with PARF.<sup>5,15</sup> In our study, the most common manifestations of PARF were lower back pain and radiating pain. Neurological defects such as weakness of lower extremity, sensory defects, and caudal equina syndrome were rare. The positive ratio of SLR test in PARF patients was similar to that in the patients with HLD alone. In contrast, the patients with PARF had more severe pain than those with HLD alone. The report of Chang et al.<sup>7</sup> showed the same result regarding the symptoms of patients having PARF being more painful. We supposed that separated osseous particles in PARF caused the severe pain in these patients.

CT was the best modality to diagnose and recognize the size, shape, and location of fracture (Fig. 2). Almost all the authors diagnosed PARF and its associated characteristics using a CT scan.<sup>20</sup> Additionally, CT scan was the best way to distinguish



**Fig. 2.** Computed tomographic axial image (A) and sagittal reconstruction image (B) represent a small fracture fragment located at superior endplate of sacrum. Arrow indicates the lesions of posterior apophyseal fracture.



**Fig. 3.** These magnetic resonance images showed the lesions of posterior apophyseal fracture. We could not exactly distinguish between the lesions of posterior apophyseal ring fracture and ruptured disc particles on these images. Arrow indicates the lesions of posterior apophyseal fracture.

calcified HLDs and particles of fracture. However, MRI is a less precise method of diagnosing PARF because it is difficult to differentiate the bony fragment from the disc or ligament that also presented with low signal intensity (Fig. 3). In terms of sensitivity, CT scan was a better method than MRI because MRI only identifies 22% of lesions.<sup>17</sup>

The most common site and level of PARF are controversial. Some authors reported that L4/L5 level was the most common level of PARF with HLD in adolescents and L5/S1 in young adults.<sup>3,21-23</sup> Other researchers presented that PARF occurred at L5/S1 level mostly in all people.<sup>5,15,22</sup> All reports about the site of PARF showed that the S1 superior endplate was the most commonly affected site.<sup>15,24</sup> Our study also revealed that L5/S1 level and S1 superior endplate were the most commonly affected sites. According to some reports including ours, the posterior part of superior vertebral endplate is a more frequently affected site than the lower endplate because the superior endplate of vertebral body was the most stressful site from functional point of view.<sup>8</sup>

The widely used classification of PARF is Takada's classification.<sup>3</sup> This method divides PARF into 3 types according to the morphology of fracture. The type 1 is simple and thin avulsion fracture of posterior vertebral endplate that does not contain the vertebral body. It has been reported that children under 13 years of age are mostly affected by this type. The type 2 is a large and thicker avulsion fracture of the posterior rim including the cartilage endplate of annulus fibrosus and is found in children over 13 years and in adolescents. Type 3 defines a small posterior vertebral body fracture larger than the vertebral rim. These fractures are found more frequently in the young adults older than 18 years. We enrolled the patients with PARF

aged between 19 and 25 years, so we predicted that type 3 was the most common type in our study, according to this report. However, the most common type in our report was type 2. For the Takada's classification is based on small groups including 29 patients and 31 fractures, so it is assumed that this difference about most common type in these age would have occurred. Other classifications are also based on small groups or retrospective review. So we suggested that the spinal surgeons should develop the systemic and faithful classification using prospective studies in large groups.

## CONCLUSION

Our study shows that the adults in early twenties have the highest incidence of PARF. The adults having PARF in their early twenties present with severe lower back pain and radiating pain than those with HLD alone. CT scan is the best way to identify this condition. Thus, we recommend that the spinal surgeons should perform a CT scan for all patients, in their young twenties, with severe radiating pain and/or lower back pain and multiple HLD lesions in patients' MRI.

## CONFLICT OF INTEREST

The authors have nothing to disclose.

## REFERENCES

1. Baba H, Uchida K, Furusawa N, et al. Posterior limbus vertebral lesions causing lumbosacral radiculopathy and the

- cauda equina syndrome. *Spinal Cord* 1996;34:427-32.
2. Epstein NE, Epstein JA. Limbus lumbar vertebral fractures in 27 adolescents and adults. *Spine (Phila Pa 1976)* 1991;16:962-6.
  3. Takata K, Inoue S, Takahashi K, et al. Fracture of the posterior margin of a lumbar vertebral body. *J Bone Joint Surg Am* 1988;70:589-94.
  4. Matsumoto M, Watanabe K, Tuji T, et al. Microendoscopic discectomy for lumbar disc herniation with bony fragment due to apophyseal separation. *Minim Invasive Neurosurg* 2007;50:335-9.
  5. Shirado O, Yamazaki Y, Takeda N, et al. Lumbar disc herniation associated with separation of the ring apophysis: is removal of the detached apophyses mandatory to achieve satisfactory results? *Clin Orthop Relat Res* 2005;431:120-8.
  6. Yang IK, Bahk YW, Choi KH, et al. Posterior lumbar apophyseal ring fractures: a report of 20 cases. *Neuroradiology* 1994;36:453-5.
  7. Chang CH, Lee ZL, Chen WJ, et al. Clinical significance of ring apophysis fracture in adolescent lumbar disc herniation. *Spine (Phila Pa 1976)* 2008;33:1750-4.
  8. Martínez-Lage JF, Poza M, Arcas P. Avulsed lumbar vertebral rim plate in an adolescent: trauma or malformation? *Childs Nerv Syst* 1998;14:131-4.
  9. Bick EM, Copel JW. The ring apophysis of the human vertebra; contribution to human osteogeny. II. *J Bone Joint Surg Am* 1951;33-A:783-7.
  10. Ehni G, Schneider SJ. Posterior lumbar vertebral rim fracture and associated disc protrusion in adolescence. *J Neurosurg* 1988;68:912-6.
  11. Savini R, Di Silvestre M, Gargiulo G, et al. Posterior lumbar apophyseal fractures. *Spine (Phila Pa 1976)* 1991;16:1118-23.
  12. Talha A, Cronier P, Toulemonde JL, et al. Fracture of the vertebral limbus. *Eur Spine J* 1997;6:347-50.
  13. Faizan A, Sairyo K, Goel VK, et al. Biomechanical rationale of ossification of the secondary ossification center on apophyseal bony ring fracture: a biomechanical study. *Clin Biomech (Bristol, Avon)* 2007;22:1063-7.
  14. Sairyo K, Goel VK, Masuda A, et al. Three-dimensional finite element analysis of the pediatric lumbar spine. Part I: pathomechanism of apophyseal bony ring fracture. *Eur Spine J* 2006;15:923-9.
  15. Akhaddar A, Belfquih H, Oukabli M, et al. Posterior ring apophysis separation combined with lumbar disc herniation in adults: a 10-year experience in the surgical management of 87 cases. *J Neurosurg Spine* 2011;14:475-83.
  16. Scarfò GB, Muzii VF, Mariottini A, et al. Posterior retroextramarginal disc hernia (PREMDH): definition, diagnosis, and treatment. *Surg Neurol* 1996;46:205-11.
  17. Epstein NE. Lumbar surgery for 56 limbus fractures emphasizing noncalcified type III lesions. *Spine (Phila Pa 1976)* 1992;17:1489-96.
  18. Peh WC, Griffith JE, Yip DK, et al. Magnetic resonance imaging of lumbar vertebral apophyseal ring fractures. *Australas Radiol* 1998;42:34-7.
  19. Laredo JD, Bard M, Chretien J, et al. Lumbar posterior marginal intra-osseous cartilaginous node. *Skeletal Radiol* 1986;15:201-8.
  20. Wu X, Ma W, Du H, et al. A review of current treatment of lumbar posterior ring apophysis fracture with lumbar disc herniation. *Eur Spine J* 2013;22:475-88.
  21. Dake MD, Jacobs RP, Margolin FR. Computed tomography of posterior lumbar apophyseal ring fractures. *J Comput Assist Tomogr* 1985;9:730-2.
  22. Handel SF, Twiford TW Jr, Reigel DH, et al. Posterior lumbar apophyseal fractures. *Radiology* 1979;130:629-33.
  23. Leroux JL, Fuentes JM, Baixas P, et al. Lumbar posterior marginal node (LPMN) in adults. Report of fifteen cases. *Spine (Phila Pa 1976)* 1992;17:1505-8.
  24. Bae JS, Rhee WT, Kim WJ, et al. Clinical and radiologic analysis of posterior apophyseal ring separation associated with lumbar disc herniation. *J Korean Neurosurg Soc* 2013;53:145-9.